



Efficacy of Oral Isotretinoin in Combination with Desloratadine in the Treatment of Acne Vulgaris at Al-Thawrah General Hospital, Sana'a, Yemen

Mutaia Abdullah Abuarjij^{1*} and Amal Ahmed Al Qtwani²

1 Department of Dermatology & Venereology, 21 September University for Medical and Applied Sciences, Sana'a, Yemen.

2 Department of Dermatology, Al-Thawrah General Hospital, Sana'a Yemen.

*Corresponding Author: Mutaia Abdullah Abuarjij, 21 September University for Medical and Applied Sciences, Sana'a, Yemen. Tel: +96777088664

Article History | Received: 01.03.2023 | Accepted: 03.05.2023 | Published: 21.07.2023

Abstract

Background: Acne vulgaris is one of the most common skin problems in adult life, especially in adolescents.

Objective: This study aimed to evaluate the efficacy of oral isotretinoin in combination with desloratadine in the treatment of acne vulgaris at Al-Thawra General Hospital, Sana'a.

Methods: The study was designed as a prospective comparative clinical trial carried out in the Department of Dermatology, Al-Thawrah General Hospital, Sana'a during the period from Jan. to June 2019. The data were collected from each patient after verbal consent. All patients (60 pt.) were randomized into 2 equal groups (study group and control group). The mean age of the study group was 27.47 ± 4.249 year while 24.07 ± 3.393 year of the control group. Both groups were treated with isotretinoin 20mg per day for 16 weeks. The study group (combined treatment) received 5mg desloratadine daily in 16 weeks. The follow-up was carried in weeks (2, 4, 8, 12, 16) for acne lesion, GAGS score, side effects of drugs and outbreak of acne.

Results: This study found that females were more affected than males and acne lesion at 16 weeks was 16.7 % in the study group in contrast to 40.0 % in the control group. After 16 weeks of treatment, GAGS score showed that both groups had good outputs response to therapy with 86.7% excellent and 13.3% good in the study group compared to 56.7%, excellent, and 40 % good response to therapy. Whereas at 16 weeks most patients had no outbreak (86.7 % in the study group and 53.3 % in the control group), 3% in the study group and 46.7 % in the control group had mild outbreak with > 5 nodules. This study observed only minor side effects of desloratadine among the study group, such as headache and self-limited infection. Side effects of isotretinoin declined more rapidly when desloratadine was

added. In contrast, this study showed that 10 % of patients had chelitis, conjunctivitis and 13.3 % of them had priorities at 16 weeks.

Conclusion: This study showed that adding oral desloratadine to the oral isotretinoin provides a better outcome and advantage in terms of efficacy and tolerability than isotretinoin treatment alone.

Key words: Acne vulgaris, Acne lesion, GAGS score.

Introduction

Acne vulgaris, simply known as acne, is a human skin disease characterized by skin with scaly red skin (seborrhea), blackheads and whiteheads (comedones), pinheads may be of inflammatory or noninflammatory forms [3]. Due to changes in pilosebaceous units, lesions are caused by androgen stimulation. Acne occurs commonly during adolescence, affecting about 80–90% of teenagers in the Western world and lower rate are reported in rural societies [4–7]. It is usually caused by increase in androgens level like testosterone mainly during puberty in both male and female [8]. It also reduces over time and tends to disappear over the age [9, 10]. The large nodules are called cysts and the severe inflammatory acne are called nodulocystic [11]. Cystic acne occurs on buttocks, groin, armpit area, hair follicles and perspiration ducts. It affects deeper skin tissue than common acne. Acne causes drugs have been developed for the treatment of acne vulgaris. In Yemen, there is a lack of data on the magnitude of the disease, as well as on the effectiveness of the different treatments often prescribed for the patients. This study aims to evaluate the efficacy of oral isotretinoin in combination with desloratadine in the treatment of acne vulgaris at Al-Thawra General Hospital, Sana'a via assessing the common presentation of acne vulgaris, determining the relationship

(papules), large papules (nodules), pimples and scarring [1]. Acne affects skin having dense sebaceous follicles in areas including face, chest and back [2]. It

scarring and psychological effects such as reduced self-esteem and in rare cases depression or suicide [12, 13]. Reports showed the incidence of suicidal tendency in patients with acne is about 7.1% [14]. Acne usually occurs during adolescence [15]. Studies have exposed the burden of affecting their global self-esteem. Between 30%-50% of adolescents experience psychological difficulties associated with their acne, and although the interface is multifaceted it can be associated with developmental issues of body image, socialization, and sexuality. Some patients are severely affected and require more than acne therapy alone. In the last 25 years, numerous topical and systemic

between acne vulgaris and gender, and assessing the side effects of both drugs used in this study.

Materials and Methods

Sixty patients of either sex were randomly assigned and enrolled for the receiving of the study prospective comparative clinical trial. It was carried out in the Department of Dermatology, at Al-Thawra General

Hospital, Sana'a during the period from Jan. to June 2019.

Inclusion Criteria: Patients of either sex presented to dermatology clinics with acne vulgaris.

Exclusion Criteria: Pregnant and lactating women. Drug induced Acne form eruptions. Drug allergy. Children less than 12 years.

Method: A complete dermatological examination to identify the lesion along with general physical examination were carried out according to the pre structured questionnaire. The samples were assigned before the start of treatment. A clinical history with duration and prognosis of lesion in past and family history was elicited.

on the appearance of new nodules at each reexamination as: No outbreak (no new lesion), Mild outbreak (< 5 nodules), Moderate outbreak (5-10 nodules) and Severe outbreak (≥ 10 nodules).

The evaluation of clinical efficacy after 16 weeks of treatment was recorded as: **Excellent:** When there is no inflammation and non-inflammation lesions, **Good:** When the lesion is reduced by $\geq 90\%$ of the number of lesions, **Fair:** When the lesion is reduced by $\geq 75-90\%$ of the number of lesions, **Moderate:** When the lesion is reduced by $\geq 50-75\%$ of the number of lesions, and **Poor:** When the lesion is reduced by $< 50\%$ of the number of lesions.

Data analysis: Data analysis was performed with SPSS v.20.0 for Windows. The results are expressed as Mean \pm SD for quantitative data and number and percentage for the 53.3% while males were 46.7% for the study group compared to 63.3 % and 36.7% for the

Sample size: A convenient sample size was used in the study, as all cases of acne vulgaris of various grades of either sex who presented to dermatology clinics were included. A group of 60 patients was randomized into 2 equal groups: study group and control group. Both groups were treated with isotretinoin 20mg per day for 16 weeks. The study group (combined treatment) received 5mg desloratadine daily for 16 weeks.

Evaluation: The number of acne lesions were counted, (Scoring GAGS (Global Acne Grading System)), and side effects after weeks 2, 4, 8, 12 and 16 of treatment were recorded. Evaluation of acne outbreak during treatment was based

categorical data. The categorical data were analysed by chi-square test to find any association between the different variables. For all the tests, a p-value of 0.05 or less was considered for statistical significance.

Ethical consideration: The aim of the study was explained to each of the participants. The patients gave verbal informed consent for clinical data. All the collected data were confidential and anonymous.

Results

A total of 60 patients were recorded during the study period. Table (1) shows that the mean age of the study group was 27.47 ± 4.249 year whereas 24.07 ± 3.393 year for the control group. This study found that females were more affected than males; the females accounted

control group respectively, Table 2. and Figure 2 show that acne lesion at 16 weeks

was 16.7 % in the study group in contrast to 40.0 % in the control group. At 16 weeks, most patients had no outbreak (86.7 % in the study group and 53.3 % in the control group) while 3%

in the study group and 46.7 % in the control group had mild outbreak with > 5 nodules response to therapy (Table 7). This study observed only minor side effects of desloratadine among the study group, such as headache and self-limited infection

(Table 5). On the other hand, after 16 weeks of treatment, GAGS score showed that both groups had good outputs response to therapy with 86.7% excellent and 13.3% good in the study group compared to 56.7%, excellent, and 40 % good in

(Figure 3 and Tables 6-8). The study group showed that 10 % of the patients had chelitis and conjunctivitis and 13.3 % of them had priorities at 16 weeks, (Table 8).

Table 1: Distribution of both groups according to age

Age (Years)	Study group	Control group	P value
Mean ± SD	27.47 ± 4.249	24.07 ± 3.393	
Minimum	20	18	0.283
Maximum	35	30	

Table 2: Distribution of patients in both groups according to sex

Sex	Study group		Control group		P value
	Freq.	%	Freq.	%	
Female	16	53.3	19	63.3	0.432
Male	14	46.7	11	36.7	
Total	30	100	30	100	

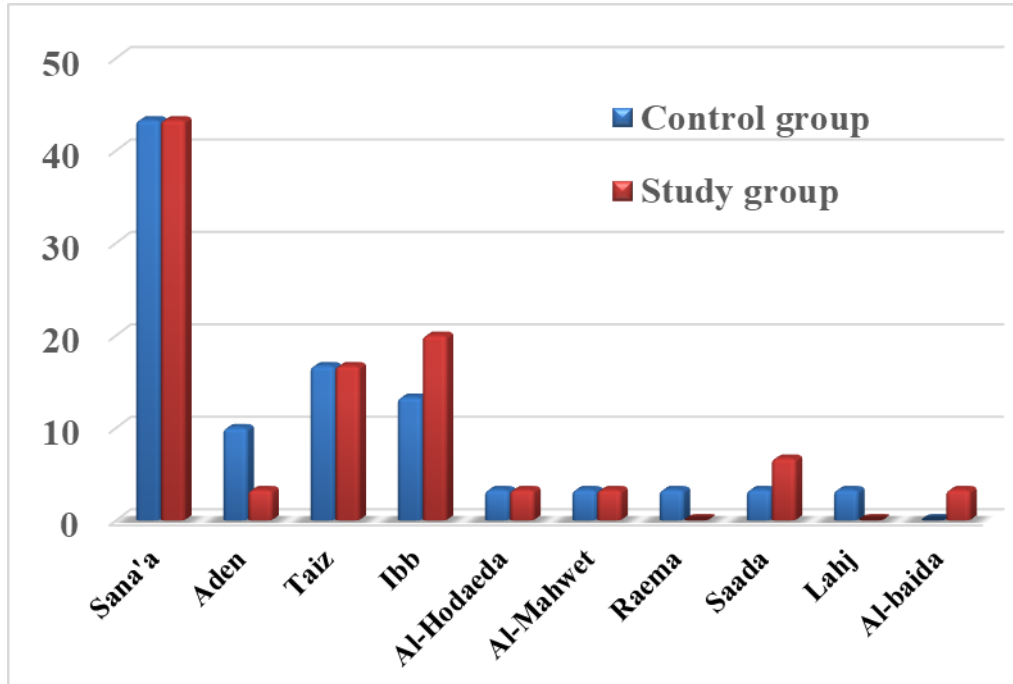


Figure 1: The Characteristics of patients in both groups before treatment in regarding to residence.

Table 3: Duration of acne in both groups

Duration	Study group		Control group		P value
	Freq.	%	Freq.	%	
4-6 months	5	16.7	7	23.3	0.519
>6 months	25	83.3	23	76.7	
Total	30	100	30	100	

Table 4: Severity of acne in both groups

Severity	Study group		Control group		P value
	Freq.	%	Freq.	%	
Mild	1	3.3	0	00.0	0.577
Moderate	17	56.7	18	60.0	
Severe	12	40.0	12	40.0	
Total	30	100.0	30	100.0	

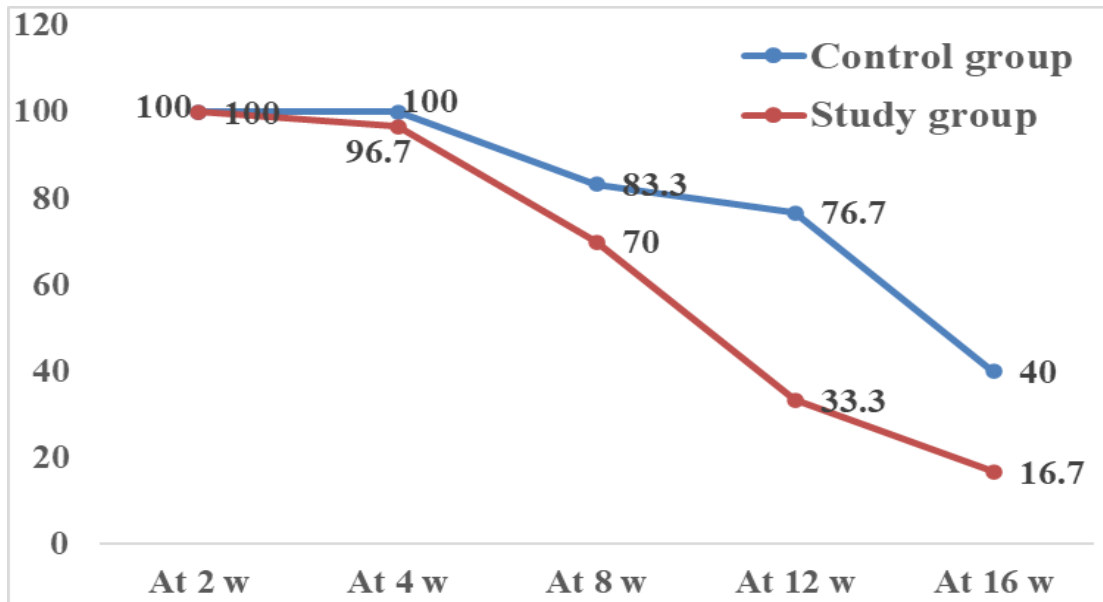


Figure 2: Follow-up of acne lesion of both groups up to 16 weeks

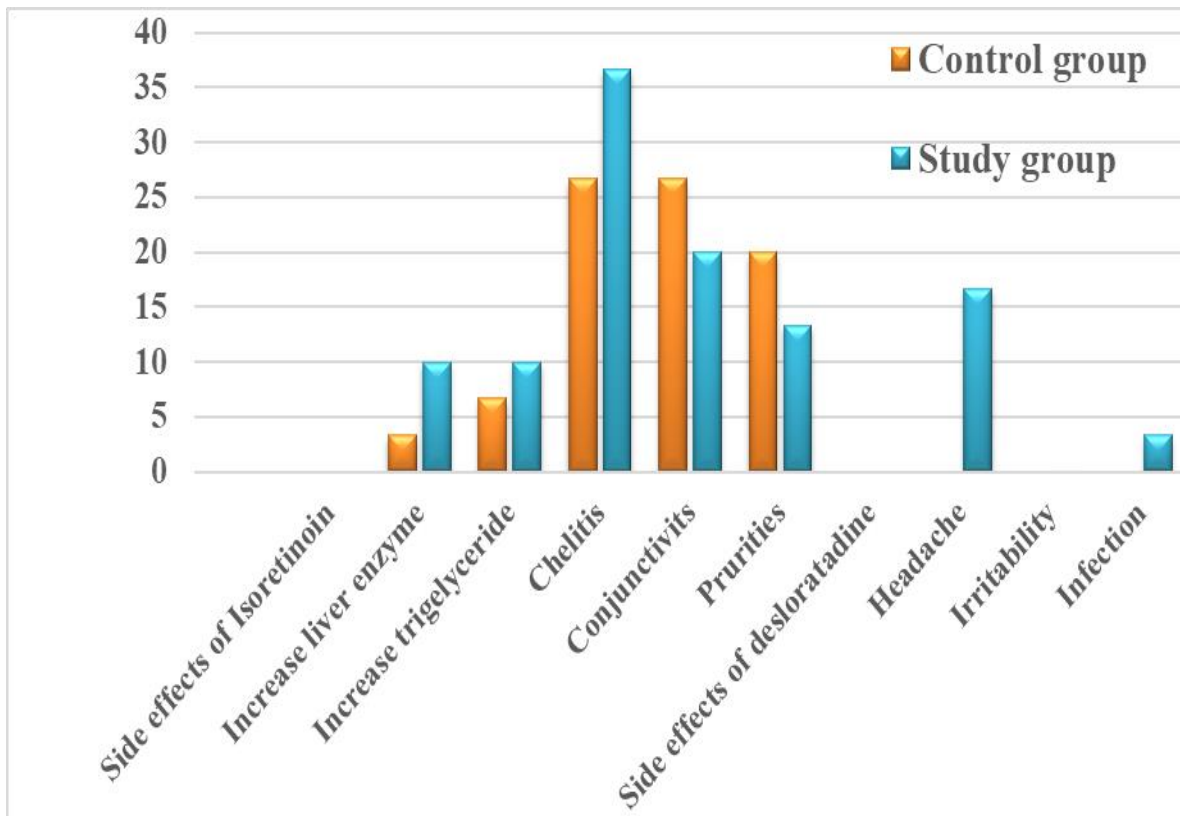


Figure 3: Comparison of side effects of drugs between the two groups at 2 weeks

Table 5: GAGS score during follow-up period

GAGS score	Study group		Control group		P value
	Freq.	%	Freq.	%	
At 2 weeks					
None	0	00.0	0	00.0	0.604
1 – 18	8	26.7	5	16.6	
19 – 30	16	53.3	17	56.7	
31 – 38	6	20.0	8	26.7	
At 4 weeks					
None	1	3.3	0	00.0	0.305
1 – 18	16	53.3	12	40.0	
19 – 30	13	43.3	18	60.0	
31 – 38	0	00.0	0	00.0	
At 8 weeks					
None	9	30.0	5	16.7	0.054
1 – 18	19	63.3	16	53.3	
19 – 30	2	6.7	9	30.0	
31 – 38	0	00.0	0	00.0	
At 12 weeks					
None	19	63.3	6	20.0	0.003
1 – 18	11	36.7	19	63.3	
19- 30	0	00.0	5	16.7	
31 – 38	0	00.0	0	00.0	
At 16 weeks					
None	26	86.7	17	56.7	0.032
1 – 18	4	13.3	12	40.0	
19 – 30	0	00.0	1	3.3	
31 – 38	0	00.0	0	00.0	

Table 6: Comparison of side effects of drugs between the two groups at 8 weeks

Side effect	Study group		Control group		P value
	Freq.	%	Freq.	%	
Side effects of Isoretinoin					
Increase liver enzyme	0	00.0	2	6.7	0.150
Increase triglyceride	1	3.3	4	13.3	0.161
Chelitis	9	30.0	30	100.0	0.000
Conjunctivits	5	16.7	30	100.0	0.000
Prurities	6	20.0	26	86.7	0.000
Side effects of desloratadine					
Headache	5	16.7			
Irritability	0	00.0			
Infection	1	3.3			

Table 7: Comparison of side effects of drugs between the two groups at 12 weeks

Side effect	Study group		Control group		P value
	Freq.	%	Freq.	%	
Side effects of Isoretinoin					
Increase liver enzyme	0	00.0	5	16.7	0.020
Increase triglyceride	1	3.3	9	30.0	0.006
Chelitis	6	20.0	30	100.0	0.000
Conjunctivits	5	16.7	28	93.3	0.000
Prurities	6	20.0	25	83.3	0.000
Side effects of desloratadine					
Headache	5	16.7			
Irritability	0	00.0			
Infection	1	3.3			

Table 8: Comparison of side effects of drugs between the two groups at 16 weeks

Side effect	Study group		Control group		P value
	Freq.	%	Freq.	%	
Side effects of Isoretinoin					
Increase liver enzyme	0	00.0	3	10.0	0.076
Increase triglyceride	0	00.0	14	46.7	0.000
Chelitis	3	10.0	29	96.7	0.000
Conjunctivits	3	10.0	27	90.0	0.000
Prurities	4	13.3	23	76.7	0.000
Side effects of desloratadine					
Headache	3	10.0			
Irritability	0	00.0			
Infection	0	00.0			

Discussion

Out of the 60 patients involved in this study, the mean age of the study group was 27.47 ± 4.249 year while the mean age of the control group was 24.07 ± 3.393 year. There was no significant difference between the two groups ($p = 0.283$). In a study by Van et al. [16] to evaluate the efficacy of oral isotretinoin used alone, and in combination with desloratadine in the treatment of moderate acne vulgaris, the mean age of the study group was 21.90 ± 4.1 years compared to the control group 22.06 ± 4.20 years. Acne vulgaris is the most common skin disease in the United States, affecting almost 85% of people ages 12-25 years old [17]. Cohen et al. [18] observed the prevalence in teenagers aged 15-17 years to be 85%. Acne occurs commonly during adolescence, affecting

about 80–90% of teenagers in the Western world and lower rate are reported in rural societies [19–22].

In another study by Thiobutot and Strauss [19], a greater number of patients were found to have acne during the middle to late teenage period. Burton et al. reported the peak age of acne as between 14-17 years in females and 16-19 years in males. This study found that the females accounted for 53.3% while the male were 46.7% for the study group compared to 63.3% and 36.7% for the control group respectively.

There was no significant difference between the two groups ($p = 0.43$). Van et al [16] in their study which was carried out among 62 patients distributed between 20 female patients and 11 male patients in the study group compared to 19 females and 12

males in the control group observed no statistically significant difference between the two groups ($p = 0.07$). It is reported that acne is more common in females 9.8% compared to males 9.0% (31). In over 40 years old subjects, about 1% of males and 5% of females have problems.

According to Dogra et al [20], acne is more common in females than in males in the ratio 3:1. Similar to Dogra et al [20], the present study showed that females were more affected than males.

In the present study, 2 (6.7%) patients of the study group had lesions on the face alone, 28 (93.3%) had lesions on face, upper chest, and back. Among the control group 20% of the patients had lesions on the face alone, 80% had lesions on face, upper chest, and back. It is reported that 95% of changes are localized on the face and on the upper part of the trunk, rarely on other body parts [23].

The present study is almost in concurrence with the above study in which face was the most common site involved followed by chest, and back. The low rate of involving the face alone among the study group in this study could be due to the severity of lesions that involved all predilection sites. This may be because acne lesions generally occur in sebaceous gland connected with vellus hair [24] and due to regional differences in the activity of type 1, 5-alpha reductase in isolated sebaceous glands.

Out of the 60 patients, 60% of the study group had blackheads lesion (open comedones), grade I, while whiteheads (closed comedones), grade II, was present among (70%). Pustules, grade III, was the most prevalent one (96.7%), redness and inflammation was present in 46.7% and

cysts (40%) taking into consideration that more than one lesion were present in one patient. Among the control group, these lesions were present as 46.7%, 63.3%, 90.0%, 43.3%, and 36.7% respectively. Our results are comparable to the study by Dhaher SA [28]. According to Cohen et al [18], acne vulgaris is a dynamic disorder characterized by the presence of comedones and usually but not always by papules, pustules, nodules, and scars. Comedones are the primary lesions of acne, the inflammatory lesions vary from small papules to pustules to large tender fluctuant nodules. True cysts are rarely found in acne.

The main goal of acne treatment is to control and treat existing acne lesions, prevent permanent scarring as far as possible, limit the duration of the disorder and to minimize morbidity. The patient should be informed on the aims involved in preventing new acne lesions while allowing the existing ones to heal. Patients should also be made aware that it may take 3–6 weeks until an improvement can be observed [25,26].

In this study, an attempt was made to evaluate if there is any beneficial effect from adding oral antihistamine (desloratadine 5 mg/day) as adjuvant therapy to the isotretinoin in a randomized clinical trial for the treatment of acne.

It is observed in this study that the GAGS score in the study group during the first two weeks of follow-up was similar to the control group with no significant differences among all weeks of follow-up ($p = 0.60$). However, in weeks 12 and 16 there was gradual reduction of scoring indicating moderate response to the

treatment. After 16 weeks of treatment, both groups had good outputs: the study group achieved 86.7% excellent, 13.3 % good, while the results in the control group were 56.7%, excellent, and 40 % good response to therapy. In Lee's study, the study group had 40% of cases clear, 50% improvement while the control group had 20% of patients clear, and 40% improvement [27].

Success in treating acne depends on several factors including an accurate diagnosis, appropriate treatment, and most importantly patient adherence. The pathogenesis of acne is generally well-understood and is easy to diagnose. The present study showed that 70% of the patients had moderate outbreak of lesion (5-10 nodules) among the study group at week 2 compared to 50% of the control group with significant difference between the two groups ($p = 0.005$). At week 4, there was a mild outbreak (> 5 nodules) among 66.7% of the study group compared to 40 % of the control group. At week 8, the study group showed only 36.7% of patients had mild outbreak compared to 46.7% of the control group. There was a significant improvement of the study group regarding the outbreak as 80% of patients had no outbreak compared to 40% of the control group. At week 16, only 13% of the study group had mild outbreak compared to 46.7% of the control group. It is reported that acne outbreaks are common side effects after starting treatment with isotretinoin for 2-4 weeks. The mechanism of the outbreak is unclear, but it is related to the release of *P. acnes* and sebaceous gland antigens, enhancing the inflammatory response. However, we

found in this study that there was a lower outbreak with time.

This study revealed that isotretinoin side effects were statistically significant among the study group compared to the control group in terms of increase of liver enzymes, increased triglyceride, and chelitis, while the pruritus and conjunctivitis showed lower rate than in the control group. This might be related to the anti-inflammatory effect of antihistamines which reduces the side effects of itching and acne outbreaks as another study reported [16].

Isotretinoin is the only therapy that targets all the primary causal factors involved in acne [28]. Oral isotretinoin, unlike antibiotics, does not act directly on microbial cells [28]. It markedly reduces the sebum excretion rate and the sebaceous gland size [29]. By reducing sebum secretion, the drug consequently decreases the follicular hyperkeratinisation and alters the microenvironment within the duct, providing greater *Propionibacterium acnes* (*P. acnes*) suppression than that seen with topical or oral antibiotics [30].

Regarding the side effects of desloratadine, this study observed only minor side effects among the study group, as headache (16.7%) and self-limited infection (3.3%). It is reported that antihistamines had a sebum regulating effect, notably, they reduce squalene release, a biomarker of sebum, [31] from sebaceous glands by blocking the overexpressed histamine receptors in sebocytes, resulting in low squalene level and this phenomenal effect will not be influenced by concomitant isotretinoin therapy because retinoids were

lacking the squalene reducing property [32].

Conclusion

This study demonstrated that adding oral desloratadine to the oral isotretinoin provides a better outcome and advantage in terms of efficacy and tolerability than isotretinoin treatment alone. Severity of acne should not only be assessed exclusively on the physical grade of acne alone, but also should include its psychological and state of mind of teenagers.

Education of dermatologists and general practitioners alike, about the psychosocial impairments of acne can help in identifying cases with acne related depression.

There is a need for incorporation of psychological intervention in the management of acne vulgaris, for improvement in the quality of life and psychological wellbeing in such cases.

The impairment of quality of life can be alleviated by appropriate acne treatment along with psychosocial support. Setting up supportive groups could also be of immense help for these patients. Family involvement can also help the patient to come out of any such distress. A proper guidance and help are rights of every individual.

References

1. Thappa D, Adityan B, Kumari R. Scoring Systems in Acne Vulgaris. *Indian J Dermatol Ve* 2009; 75(3): 323–326p.
2. Benner N; Sammons D. Overview of the Treatment of Acne Vulgaris, *Osteopath Family Physic* 2013; 5(5): 185–190p.
3. Harper JC. Acne Vulgaris, *eMedicine*, 2009.
4. Taylor M, Gonzalez M, Porter R. Pathways to Inflammation: Acne Pathophysiology, *Eur J Dermatol* 2011; 21(3): 323–333p.
5. Dawson AL, Dellavalle RP. Acne Vulgaris, *BMJ* 2013; 346: f2634p.
6. Berlin DJ, Goldberg AL. Acne and Rosacea Epidemiology, Diagnosis and Treatment, London: Manson Pub, 2012, 8p.
7. Spencer EH, Ferdowsian HR, Barnard ND. Diet and Acne: A Review of the Evidence, *Int J Dermatol* 2009; 48(4): 339–347p.
8. James WD. Acne, *New Engl J Med* 2005; 352(14): 1463–1472p.
9. Hsu A, Kenneth J. *Manual of Dermatologic Therapeutics*, Lippincott Williams & Wilkins, 2007.
10. Laurence A. *Looking Good, the Australian Guide to Skin Care*, Cosmetic Medicine and Cosmetic Surgery, AMPCo, Sydney, 2006.
11. Thiboutot DM, Strauss JS. Diseases of the Sebaceous Glands. In Burns, Tony; Breathnach Stephen; Cox, Neil; Griffiths, Christopher, *Fitzpatrick's Dermatology in General Medicine*, (6th Ed.). New York: McGraw-Hill, 2003, 672–687p.
12. Goodman G. Acne and Acne Scarring-the Case for Active and Early Intervention, *Aust Fam Physician* 2006; 35(7): 503–504p.
13. Purvis D, Robinson E, Merry S, *et al.* Acne, Anxiety, Depression and

- Suicide in Teenagers: A Cross-sectional Survey of New Zealand Secondary School Students, *J Paediatr Child Health* 2006; 42(12): 793–796p.
14. Picardi A, Mazzotti Eva, Pasquini P. Prevalence and Correlates of Suicidal Ideation among Patients with Skin Disease, *J Am Acad Dermatol* 2006; 54(3): 420–426p.
 15. Nambudripad DS. *What are the Common Skin Disorders? Freedom from Eczema*, Delta Publishing, 2008, 27p.
 16. Van T N, Thi L D, Trong H N, et al . Efficacy of Oral Isotretinoin in Combination with Desloratadine in the Treatment of Common Acne Vulgaris in Vietnamese Patients *Maced J Med Sci.* 2019 Jan 30; 7(2):217-220.
 17. Bergfeld WF. The evaluation and management of acne: economic considerations. *J Am Acad Dermatol* 1995;32:S52-56.
 18. Cohen BA, Prosen P, Schachner AL. Acne. In: Schachner AL, Hansen CR, Editors. *Paediatric dermatology*, 2nd Edn., Vol.2., New York: Churchill Livingstone Inc., 1995. p.661-683.
 19. Thiboutot DM, Strauss JS. Diseases of sebaceous glands. In: Freedberg IM, Eisen AZ, Wolff K, Austen KF, Goldsmith LA, Katz SI, Editors. *Dermatology in general medicine: 6th Edn., Vol.1*, New York: McGraw Hill, 2003. p.672-687.
 20. Dogra J, Aneja N, Saxena VN. Oral guggulipid in acne vulgaris management. *Ind J Dermatol Venereol Leprol* 1990; 56: 381-383.
 21. Tan JKL, Vasey K, Fung KY. Beliefs and perceptions of patients with acne. *J Am Acad Dermatol* 2001; 44 : 439-445.
 22. Pearl A, Arnold B, Lello J, Birchall NM. The impact of acne : a study of adolescents attitudes, perceptions and knowledge. *NZ Med J* 1998; 111: 265-271.
 23. Bergler-Czop B, Brzezińska-Wcisło L. Dermatological problems of the puberty. *Postep Derm Alergol* 2013; 30: 178-187.
 24. Tutakne MA, Chari KVR. Acne, Rosacea and perioral dermatitis. In: Valia RG, Valia AR, Editors. *IADV text book and Atlas of dermatology*: Mumbai: Bhalani Publishing House, 2001. p.689-710.
 25. Dhaher SA, Jasim ZM. The adjunctive effect of desloratadine on the combined azithromycin and isotretinoin in the treatment of severe acne: Randomized clinical trial. *J Dermatol Dermatol Surg* 2018;22:21-25
 26. Lavers, I. Diagnosis and management of Acne vulgaris. *Nurse Prescr.* 2014, 12, 330–336. [CrossRef]
 27. Feldman, S.; Careccia, R.E.; Barham, K.L.; Hancox, J. Diagnosis and treatment of acne. *Am. Fam Physician* 2004, 69, 2123–2130. [PubMed]
 28. Lee HE, Chang IK, Lee Y, Kim CD, Seo YJ, Lee JH, Im M. Effect of antihistamine as an adjuvant treatment of isotretinoin in acne: a randomized, controlled comparative study. *Journal of the European Academy of Dermatology and Venereology.* 2014; 28(12):1654-1660.

29. Nast A, Bayerl C, Borelli C, Degitz K, Dirschka T, Erdmann R, et al. S2k - Guideline on the therapy of acne. *Journal of the German Society of Dermatology* 2010;379(9813):361-372.
30. King K, Jones DH, Daltrey D, Cunliffe WJ. The effect of 13-cis retinoic acid on the skin microflora of patients with severe acne. *Journal of Investigative Dermatology* 1982;78 (4):328. CENTRAL: CN-00321308
31. Pelle E, McCarthy J, Seltsmann H, Huang X, Mammone T, Zouboulis CC, et al. Identification of histamine receptors and reduction of squalene levels by an antihistamine in sebocytes. *J Invest Dermatol* 2008;128:1280-5.
32. Zouboulis CC, Korge B, Akamatsu H, Xia LQ, Schiller S, Gollnick H, et al. Effects of 13-cis-retinoic acid, all-trans-retinoic acid, and acitretin on the proliferation, lipid synthesis and keratin expression of cultur